

An ECG Primer

Quick Look

Cardiac Monitoring System - p. 64

ECG Paper - p. 73

Lead Polarity and Vectors - p. 77

Basic ECG Components - p. 79

Heart Rate and Pulse Rate - p. 91

Summary - p. 94

Chapter Quiz - p. 95

The first three chapters laid the ground work for the chapters that follow. In fact, two vital steps in rapid ECG interpretation have already been addressed: 1) Is the rhythm too fast or too slow? and 2) Is the QRS complex wide or narrow? ECG interpretation refers to both cardiac mechanics and the heart's electrics.

Except for a brief look at the QRS complex in the last chapter, this is our first foray into the realms of the ECG. On first glance, the ECG might appear formidable, mysterious and undecipherable. Don't believe it! This chapter, an ECG primer, quickly reveals the simplicity of the ECG.

This chapter begins with the cardiac monitoring system, particularly the three and five lead systems. Methods to determine heart rate are outlined and reinforced with practice exercises. The waveforms, intervals, segments and complexes of an ECG round out this chapter.

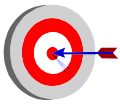
Reading an ECG can be fairly simple. The key is to find meaning in what you see on a cardiac monitor or on ECG paper. Making sense of the various components of the ECG is what this chapter is all about. Yes, it's about time!

I saw it, but I did not realize it.

Elizabeth Peabody

Cardiac Monitoring System

Since Dr. Willem Einthoven invented the first “electrokardiogram” in 1902, the electrical activity of the heart has been recorded. The ability to recognize a normal cardiac rhythm and recognize dysrhythmias didn't become common place in health care facilities until the 1960s.



Terminology

The electrocardiogram was initially called an **electrokardiogram** or EKG. While the term EKG continues to get a fair amount of use, “ECG” will be used in this book despite its similar sound to EEG. Also, the term arrhythmia is synonymous with dysrhythmia.

In the past 4 decades, great strides have been made in the recording and interpretation of electrocardiogram. Despite technological advances in cardiac diagnostics (i.e. electrophysiology studies), the electrocardiogram (ECG) remains a non-invasive, quick and effective diagnostic tool.

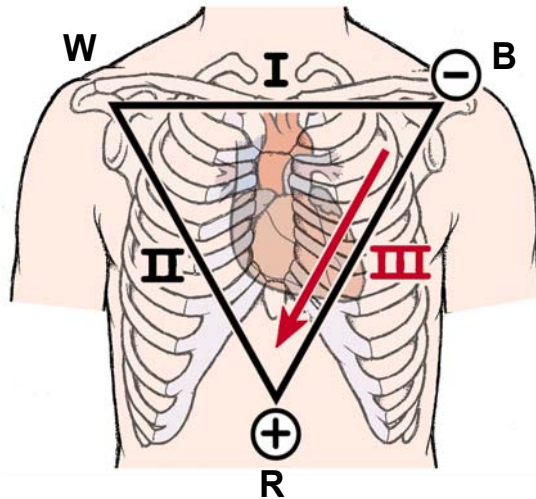
Your first exposure to an ECG might be compared to trying to make sense of a foreign language. Without any knowledge of the structure or rules, understanding is all but impossible. The good news is that the structures or components of an ECG can be quickly addressed. Also, the rules to understand and interpret an ECG are few and easily learned. The first step is to be able to capture electrical heart rhythms on a cardiac monitor and on paper.

The 3 Lead Wire ECG System (Einthoven's Triangle)

The three lead ECG has been around for some time. In fact, the three lead ECG recently celebrated its 100th birthday. While the five lead ECG is gradually becoming the norm, the three lead ECG continues to be used in emergency departments, telemetry monitoring, and during medical procedures. Three colored wires connect to three electrodes to form a triangle - Einthoven's triangle (see Figure 4.1 on page 65).

The three electrodes are colored white, black and red. These colors are not universal. Two coloring schemes exist for electrode placement, originating from two standards bodies: the American Heart Association (AHA) and the International Electrotechnical Commission (IEC). The coloring scheme followed in this book adheres to the standard advocated by the AHA (refer to Table 4.1 on page 65).

Figure 4.1 The 3 Lead Cardiac Monitoring System



W - white lead, always negative polarity

B - black lead, positive for lead I, negative for lead II

R - red lead, always positive polarity

Figure 4.1 depicts the standard three lead system that forms Einthoven's triangle. Note that while the red electrode is usually placed near the left lateral base of the chest, the electrical reference point for the red electrode tends to reside as shown. The arrow that is directed parallel to lead III represents a vector. If the wave of electrical depolarization moves parallel and in the same direction as this vector, the waveforms will be upright and the tallest in amplitude (this is covered later in this chapter).

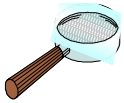For monitoring purposes with the three lead system, the white electrode is placed just below the clavicle (collarbone) on the right shoulder. When utilized - in leads I and lead II - the white electrode has a negative polarity. In accordance with the AHA, the end of the electrode cable is labelled "RA" for right arm.

Table 4.1 Electrode Location Standards of the AHA and the IEC

AHA (North America)		Location	IEC (Europe)	
Inscription	Colour		Colour	Inscription
RA	White	Right Arm	Red	R
LA	Black	Left Arm	Yellow	L
RL	Green	Right Leg	Black	N
LL	Red	Left Leg	Green	F
V1-6	Brown	Chest	White	C1-6

North America uses the AHA standards and Europe follows the IEC. Other regions are mixed. Knowing the standards in your region ensures correct electrode placement.

The red electrode, an electrode with positive polarity in lead in leads II and III, is connected below the left pectoral muscle near the apex of the heart. The end of the red electrode cable is usually labelled “LL” for left leg.



Electrodes are optimally placed directly on dry skin. Many electrode manufacturers stress: 1) shaving the skin if necessary; 2) removing dead skin cells by rubbing the area with a rough paper or cloth; 3) using electrodes from air tight packages; and 4) paying attention to expiry dates on the electrodes. While common practice may not place great importance on the later three items, these criteria may be especially useful when troubleshooting an unclear ECG tracing.

The black electrode is connected below the left clavicle near the shoulder. Often labelled “LA” for left arm, the black electrode switches polarity dependent on the lead chosen. With lead I, the black electrode becomes positive (white is always negative). The black electrode assumes a negative polarity in lead III.

Various mnemonics might help ensure correct lead placement. Two examples are:

White to the right. Red to the ribs. Black on top.

White to the right. Smoke (black) over fire (red).

Just the same, we can always just look for reference from the end of the electrodes and place them accordingly.

Electrodes are best connected to the skin in an area with minimal muscle activity. The cardiac monitor picks up any electrical activity, including any other muscle twitching in the vicinity. There is some question about whether the electrodes should be placed on bone, on muscle, under or over breasts. For dysrhythmia monitoring, electrodes should be optimally placed to get the clearest tracing. Changing electrode positions, though, by very little often changes the ECG. The key is consistency.

The three lead system provides three views of the heart. **Locating the positive electrode is crucial** to determining which area of the heart is viewed electrically. Metaphorically, the positive electrode serves as a mini-video camera aimed at the heart in the direction of the negative electrode. These leads and their corresponding electrodes do not sit right on the heart. Rather, their vantage points offer a surface, frontal view of the heart. Figure 4.2 depicts the regions viewed by each lead.

Figure 4.2 The 3 Lead Views of the Heart

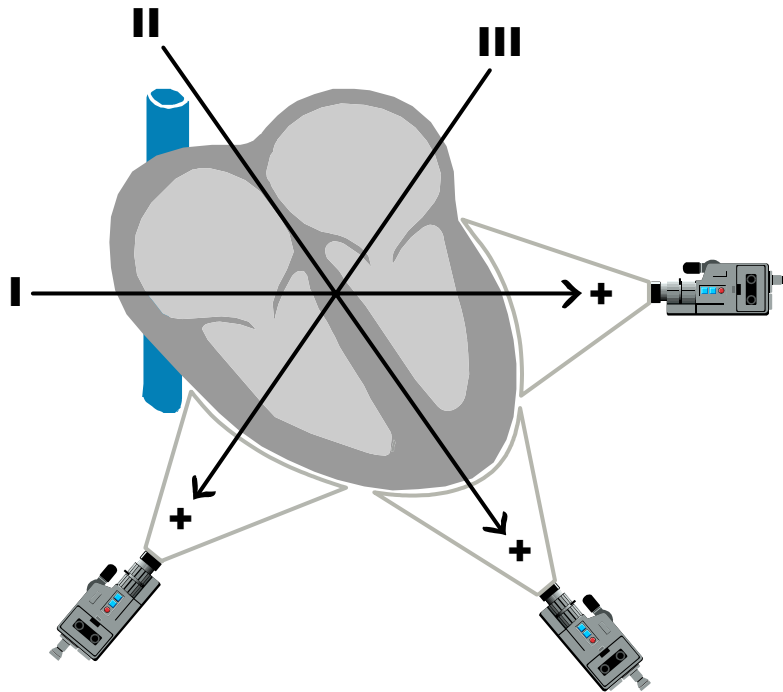


Figure 4.3 illustrates the views of the three lead system. Each of the leads view the heart from the perspective of the positive electrode towards the negative electrode.

Lead I provides a left lateral view of the heart. Perhaps the lead most often chosen for cardiac monitoring, lead II is an inferior lead viewing the apex of the heart. Lead III also provides an inferior view. Together, the three leads are able to simultaneously monitor multiple regions of the heart.

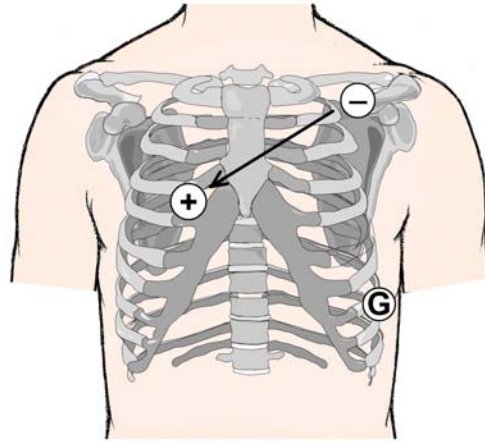
Table 4.2 The Chambers Viewed by the Three Lead System

Lead	Views	Heart Chambers
Lead I	Lateral	Left ventricle, left atrium
Lead II	Inferior	Left and right ventricle,
Lead III	Inferior	Right and left ventricles

Table 4.2 provides summarizes the chambers viewed by the three lead ECG system. Both leads II and lead III are inferior leads while lead I is a lateral lead. Each of the leads of the three lead system are bipolar leads since each lead has both a positive and a negative electrode. Note that the electrode that is not polarized (positive or negative) for each lead serves instead as a ground electrode (i.e. the black electrode with lead II).

Einthoven's three lead system is the most commonly used three lead cardiac monitoring system today. Some centers, though, choose to use a modified central lead (MCL_1) as part of the three lead system. This is sometimes also referred to as the modified *chest* lead. This lead is often used together with lead II to help distinguish between supraventricular and ventricular tachycardias.

Figure 4.3 Modified Central Lead (MCL_1)



The modified central lead, called MCL_1 , is established with the cardiac monitor set to lead I, with the white electrode a negative polarity, the black electrode a positive polarity (the red electrode serves as the ground). Upon examining the 12 lead ECG in chapter 7, lead MCL_1 will be revealed to be similar to the precordial lead V_1 . Note that lead V_1 is superior to lead MCL_1 as a diagnostic lead for dysrhythmias and for myocardial ischemia monitoring.

The modified central lead is created by placing the positive electrode at the 4th intercostal space just to the right of the sternum and the negative electrode below the left clavicle near the shoulder. The ground electrode (red) electrode can be placed anywhere on the body (refer to Figure 4.3).

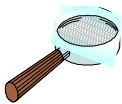
Whether the standard or a modified version of the three lead system is used, there is an important point to consider. Practically any lead will suffice for dysrhythmia monitoring. For tasks such as myocardial ischemia monitoring, though, each lead provides information *specific only to the region viewed*. For example, Lead I can provide signs of left ventricular ischemia, but only rarely signs of right ventricular ischemia.

For example, take a patient experiencing cardiac ischemia of the inferior region. In all leads, a sinus rhythm is identified. But evidence of ischemia - typically found in the inferior leads II and III, may be absent in lead I. If only lead I was monitored, this ischemic event would most likely be missed entirely (about 70-80% of all ischemic episodes occur with no symptoms). The bottom line: **the more lead views monitored, the better.**

The 5 Lead Wire ECG System

In the 1990s, research papers challenged the efficacy of lead II for dysrhythmia monitoring. One paper reported that supraventricular tachycardia (SVT) and ventricular tachycardia (VT) was correctly identified only about a third of the time when using lead II. If a 12 lead ECG was used, correct identification of either SVT or VT occurred 90% of the time (refer to “Suggested Readings and Resources” on page 100). A single lead II continues to be commonly used today.

Lead V_1 of the 12 lead ECG was found to be the single best lead. Lead V_1 most often displayed the waveforms required to correctly distinguish between SVT and VT. Since lead MCL_1 is purported to provide a similar view to lead V_1 , these two leads were compared. Lead V_1 came out on top, with ECG interpretation using lead MCL_1 arriving at an incorrect diagnosis for either SVT or VT about 22% of the time. Clearly, concurrent display of multiple lead views, including lead V_1 , is advantageous.



Lead V_1 is addressed in more detail in chapter 7, The 12 Lead ECG. Lead V_1 is a unipolar lead that views the heart directly below. This lead is created by the combination of electrodes to simulate a negative pole at the anatomical centre of the heart, with the positive electrode located at the 4th intercostal space placed just right of the sternum. As a result, lead V_1 views the heart directly below the position of this positive electrode. In order to provide a true lead V_1 , a 5 lead wire system is required.

Since the release of these findings, cardiac monitors have been developed with the ability to view multiple leads simultaneously. While 3 lead wire systems continue to be provided as standard equipment, most ECG monitors come with optional 5 lead wire systems.

These newer cardiac monitors come with several advantages. As mentioned, multiple lead views offer a more comprehensive electrical picture of the heart. For tasks such as ischemia monitoring, multiple lead views increase the likelihood that ischemic episodes are detected. For dysrhythmia monitoring, the case for multiple lead views is well established. To combine the old standard lead II with the preferred lead V_1 requires a 5 lead wire system, a useful option with the new cardiac monitors.

In addition, the multiple view monitor can provide a more balanced electrical representation of both the right and left sides of the heart. While lead II can provide a good view of the left ventricle (apex), lead V_1 can provide a sternum and a partial right-sided view of the heart. Several possible electrode configurations exist. One example of a 5 lead wire ECG schematic is provided in Figure 4.4 on the next page.

Figure 4.4 Electrode Placement for a Standard 5 Lead ECG System Using Lead V₁

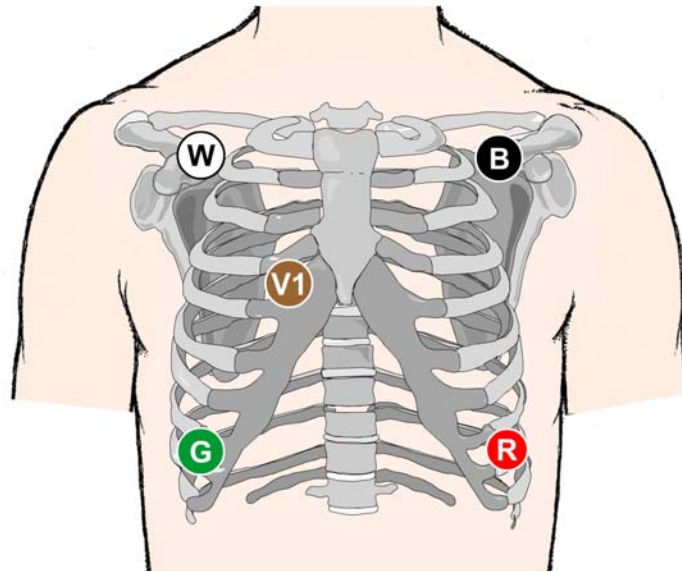
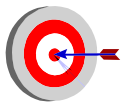


Figure 4.4 illustrates a standard 5 lead wire ECG configuration. The five electrodes includes four limb electrodes and one precordial chest lead (V₁). The limb leads are identical to the limb leads of a 12 lead ECG: right arm (RA), left arm (LA), right leg (RL) and left leg (LL).

Connecting a patient to a 5 lead wire ECG system is simple. The white, black and red electrodes are located in identical positions as with the 3 lead ECG. The green electrode is located opposite the red electrode. The brown precordial lead V₁ is located to the right of the sternal border at the 4th intercostal space (ICS). All but lead V₁ is created with four limb electrodes that would be placed on the wrists and ankles for the 12 lead ECG. The electrodes are placed on the torso for convenience.



The four limb electrodes - right arm, right leg, left arm and left leg - are commonly placed on the patient's wrists and ankles when taking a 12 lead ECG. For monitoring purposes, electrodes connected to the wrists and ankles is less than convenient as the lead wires would prove cumbersome. Therefore, the limb electrodes are placed on the torso near the junction of each limb. This placement also tends to reduce problems such as loose or moving electrodes which can add noise to an ECG tracing, called **motion artifact**. Note that since the limb electrodes in a 5 lead wire system are placed closer to the heart than the placement for a 12 lead ECG, the ECG of the same leads (i.e. lead II from a 5 lead system and a 12 lead ECG) is seldom identical.

Other 5 lead electrode configurations are also used. For example, lead V₁ can be switched to lead V₅ to monitor the lateral left ventricle and atrium when suspecting a troublesome circumflex artery. The electrode for lead V₅ is placed at or just below the

5th intercostal space at the anterior axillary line (refer to Figure 4.5). Often the precordial lead used (V_{1-6}) depends on a patient's history and the chosen monitoring task (i.e. dysrhythmia and/or ischemia monitoring).

Figure 4.5 Electrode Placement for a Standard 5 Lead ECG System Using Lead V_5

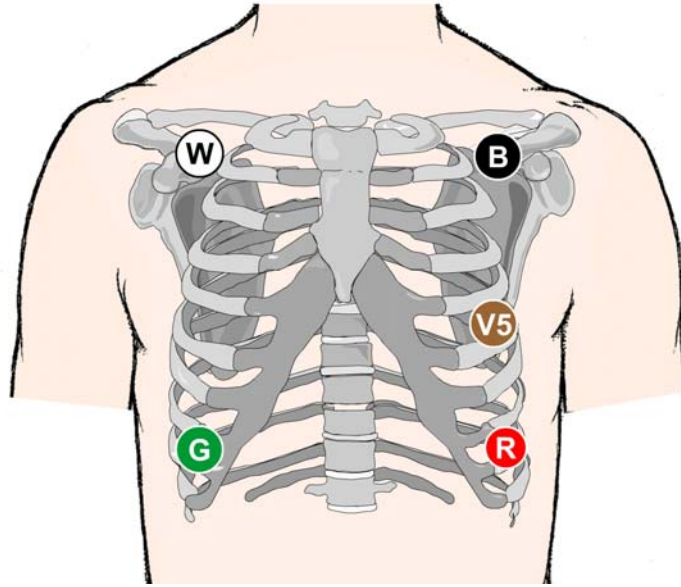


Figure 4.5 depicts a 5 lead wire ECG system that uses the four limb electrodes and the precordial lead V_5 . Lead V_5 is positioned to monitor the lateral aspect of the left ventricle.

The 5 lead wire ECG systems mentioned thus far provide 5 lead views. As mentioned earlier, a 12 lead ECG is a superior diagnostic tool both for dysrhythmia monitoring and for other tasks such as ischemia monitoring. While some cardiac monitor manufacturers include a 10 wire cable to enable real-time 12 lead ECG monitoring, these cables tend to be bulky and restrictive.

In an effort to reap the advantages of 12 lead views while keeping the monitoring system practical, reduced-lead set technologies have been developed using five or six lead wires. Philips Medical Systems developed the EASI™ lead system using a 5-cable system to estimate a 12 lead ECG. General Electric Medical Systems developed the interpolated 12 lead system using a 6-cable system. Refer to figures 4.6 and 4.7 for schematics on each of these reduced-lead set technologies.

The EASI™ lead system uses a 5 cable connector. The electrodes are configured as follows:

- the brown electrode (labelled **E** on the electrode) is located along the sternum between the white and red electrodes, horizontal with the 5th ICS;

- the red electrode (labelled **A** on the electrode) is located opposite the white electrode, at the left mid-axillary line at the 5th ICS;
- the black electrode (labelled **S** on the electrode) is located along the upper sternum below the sternal angle;
- the white electrode (labelled **I** on the electrode) is located at the right mid-axillary line at the 5th ICS;
- the green or ground electrode can be positioned at a convenient location anywhere on the torso.

The EASI™ lead system has a well established track record, being utilized by the Zymed and Agilent cardiac monitors among others.

Figure 4.6 The EASI™ Lead System

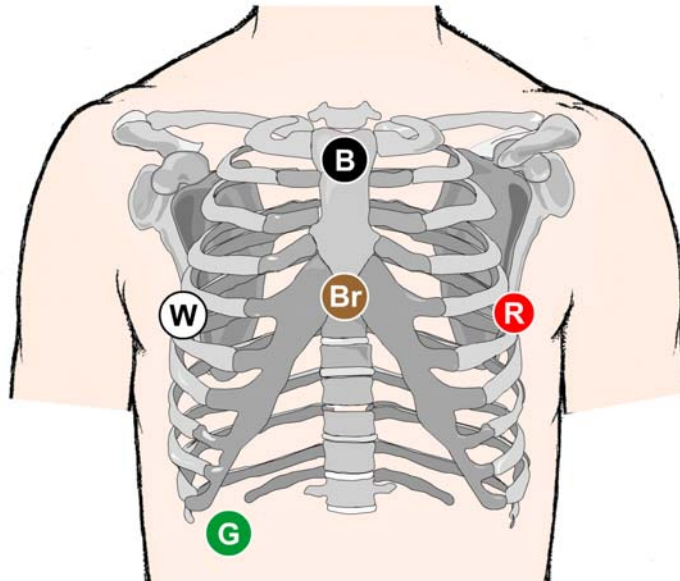


Figure 4.6 illustrates the EASI™ lead system. The electrodes which are labelled according to the acronym EASI are colored as shown: B-black, Br-brown, W-white, R-red, and G-green.

The interpolated 6 wire ECG system can also deliver real-time 12 lead ECG monitoring. The electrode configuration is close to the standard 5 lead wire ECG system with four limb electrodes but with two precordial electrodes located at lead V1 and lead V5 (refer to Figure 4.7 on the next page). The interpolated lead system is offered with Marquette cardiac monitoring systems.

Figure 4.7 Interpolated 12 Lead System Using a 6 Wire Cable

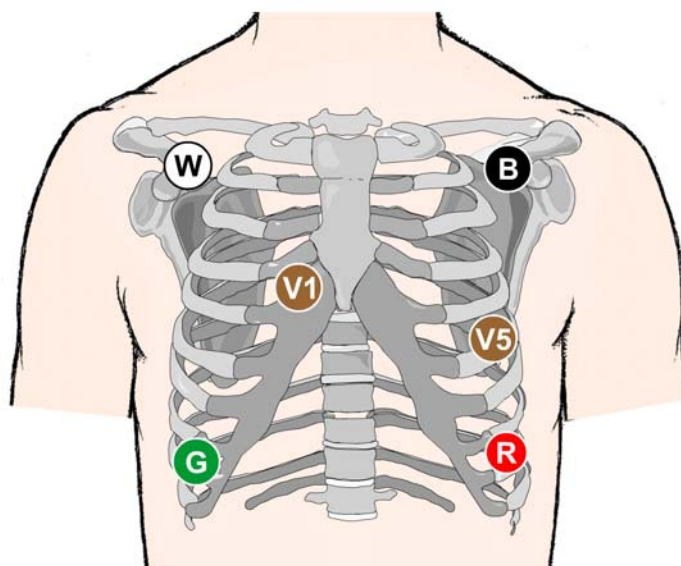


Figure 4.7 illustrates General Electric Medical Systems' interpolated 12 lead ECG cardiac monitoring system. This reduced lead set technology estimates a real-time 12 lead ECG system.

Regardless of the ECG lead system used, effective dysrhythmia and ischemia monitoring is possible only with quality ECG tracings. The use of fresh electrodes and the preparation of the patient's skin are all important steps to reduce motion artifact. Accurate placement of the ECG electrodes ensure consistent ECG readings that are worthy of comparison.

If at all possible, take advantage of multiple lead views including lead V_1 . Multiple lead views, particularly the reduced-lead set 12 lead ECG, are superior to a single lead view whatever the purpose of ECG monitoring. Before moving ahead, challenge yourself to a flash quiz on the cardiac monitoring system.

ECG Paper

Cardiac monitors usually offer two mediums to help identify ECGs: the dynamic ECG viewed on the monitor's display screen and the static ECG printed on paper. While the screen of a cardiac monitor is useful for recognizing and interpreting rhythms, printing out the ECG on specialized paper provides a much more robust electrical picture of the heart. ECG paper allows for concise measuring of rates, intervals, segments and waveforms.

An ECG is a graphical display of electrical energy generated by the heart over time. ECG graph paper records cardiac electrical activity at a rate of 25 mm/second. The paper is divided into small 1 mm squares with thicker lines every 5 mm.

It follows then that the width of an ECG tracing is a **measurement of time**. For example, a horizontal accumulation of 25 small 1 mm squares measures electrical activity over one second (as does 5 large squares produced by the thick lines). A six second strip contains a cross-section of 150 small 1 mm squares (6 seconds x 25 small squares/second) or 30 large squares.

Figure 4.8 ECG Paper and the Measurement of Time

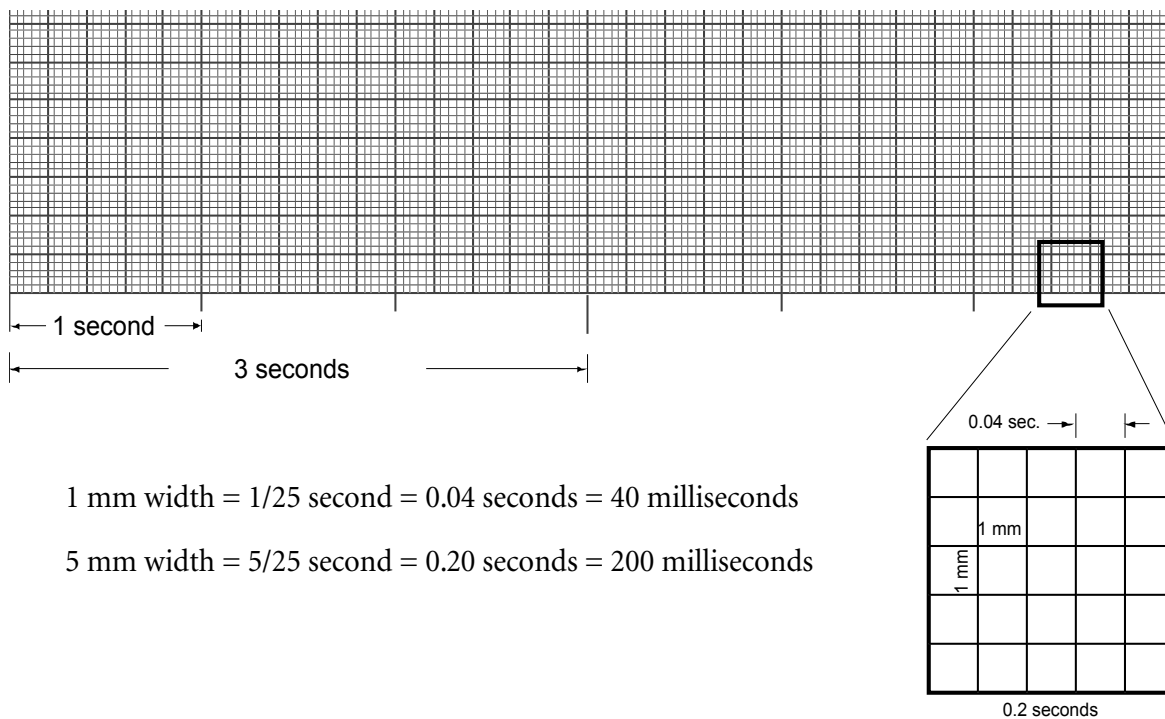


Figure 4.8 provides details of ECG paper. Note the larger hash marks that indicate 3 second intervals. Two 3 seconds intervals (6 seconds) is often used to determine heart rate.

Most brands of ECG paper also include hash marks that extend the thicker vertical lines to provide a visual reference for periods of one second and three seconds. This is depicted in Figure 4.8. These hash marks occupy either the top or bottom of the ECG paper strip.

The height (amplitude) measures electrical **voltage**. If calibrated properly, a waveform with a height of 10 mm equals 1 millivolt. The comparative height or depth of waveforms can yield significant insight about the heart (i.e. ischemia monitoring).

Flash Quiz 4.1

1. The 3 lead wire system is used to create which lead views (circle all that apply):

- a) lead I
- b) lead II
- c) lead III
- d) lead MCL₁
- e) lead V₁

2. In North America, the right arm limb electrode is colored:

- a) black
- b) white
- c) brown
- d) red

3. In North America, the red cable/electrode has a (positive, negative) polarity.

4. With lead I, the cables (electrodes) used are the _____ cable and the _____ cable.

5. To minimize motion artifact, electrodes should (circle all that apply):

- a) be taken from vacuum sealed packages
- b) be moistened with saline prior to placement
- c) be further reinforced with tape or glue
- d) be placed on skin that has been cleared of dead cells and hair

6. Lead II is well established as the best lead for dysrhythmia monitoring.

True or False

7. Electrodes should never be placed over breast tissue or bone.

True or False

Answers: 1. a),b),c),d) 2. b); 3. positive; 4. white, black; 5. a),d); 6. False; 7. False;

8. A white electrode is placed near the left shoulder below the clavicle. A black electrode is placed at the 4th intercostal space to the right of the sternum. In a 3 wire ECG system, the lead created is called:

- a) lead I
- b) lead II
- c) lead III
- d) lead MCL₁

9. The EASI reduced-lead set can provide 12 ECG views.

True or False

10. An ECG lead views the heart from the perspective of the (positive, negative) electrode looking towards the (positive, negative) electrode.

11. Each horizontal millimeter of ECG paper measures (circle all that apply):

- a) 0.20 seconds
- b) 0.04 seconds
- c) 1/25 of a seconds
- d) 0.1 millivolt

12. Each vertical millimeter of ECG paper measures (circle all that apply):

- a) 0.04 seconds
- b) 1 millivolt
- c) 0.1 millivolt
- d) amplitude of cardiac electrical activity

13. Thicker lines divide the ECG paper into larger (5 mm, 10 mm, 15 mm) squares that equal a period of (0.04, 0.01, 0.2, 1) seconds.

14. The speed standard for the printing of ECG paper is 25 mm per second.

True or False

15. If a QRS complex is present once every 5 large squares, the ventricles depolarize at a rate of (30/minute, 45/minute, 60/minute, 90/minute).

Lead Polarity and the Direction of Waveforms

Before we examine the waveforms expected on any ECG, a brief account of vector theory is required to make sense of these waveforms. A depolarizing wave moves through the myocardium *on average* along a trajectory or vector. A **vector** is a force moving in a direction symbolized by an arrow. The larger the force, the larger the arrow.

For example, an impulse initiated by the SA node moves towards the AV node and the left atrium. On average the depolarizing wave travels down and to the left. Atrial depolarization, then, has a vector that points down and towards the left. This average vector is the **electrical axis** of atrial depolarization (refer to Figure 4.9).

Figure 4.9 Vectors and the Electrical Axis

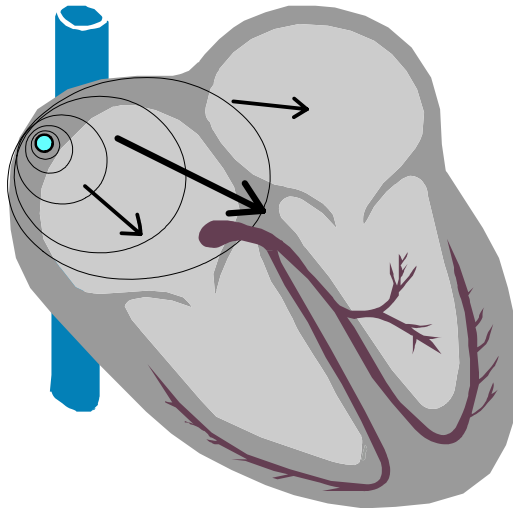


Figure 4.9 provides a graphical example of contributing electrical vectors (small arrows) that average to form the mean direction of depolarization, known as the electrical axis (large arrow). It is common for the electrical axis of the atria to point down and to the left.

The depolarization of the myocardium is represented on an ECG by a series of waveforms, one for atrial depolarization and soon after a larger waveform for ventricular depolarization. While an in depth discussion of each of these waveforms is forthcoming, an important characteristic shared by all ECG waveforms is the direction of a wave. Is the waveform upright or is it pointing downwards? A simple observation but one packed with significance.

Every lead view of an ECG has a positive electrode. As mentioned earlier, the heart is viewed electrically from the vantage point of the positive electrode. The positive electrode is important for another reason as well. A **depolarizing wave travelling towards the positive electrode produces an upright waveform**. This principle is pivotal in the quest to fully understand the ECG.



A depolarizing electrical wave that is directed towards a positive lead produces an upright waveform on an ECG. Conversely, an inverted waveform results when a depolarizing wave moves away from a positive lead.

Take an ECG tracing from the bipolar lead II. The positive red electrode is located near the apex of the heart. As a result, the apex of the heart is best viewed by lead II. Consider as well the depolarizing atrial wave (P wave) with respect to this positive red electrode. A depolarizing wave travelling from the SA node out to the left atrium and the AV node is directed towards the positive electrode in lead II. The P wave produced on lead II, then, would be upright (refer to Figure 4.9).

Alternately, an impulse originating from the AV junction depolarizes across the atria away from the positive red electrode. A resulting inverted P wave provides compelling evidence that this is a junctional rhythm initiated by the AV junction.

Figure 4.10 Atrial Depolarization, Vectors and the P Wave in Lead II

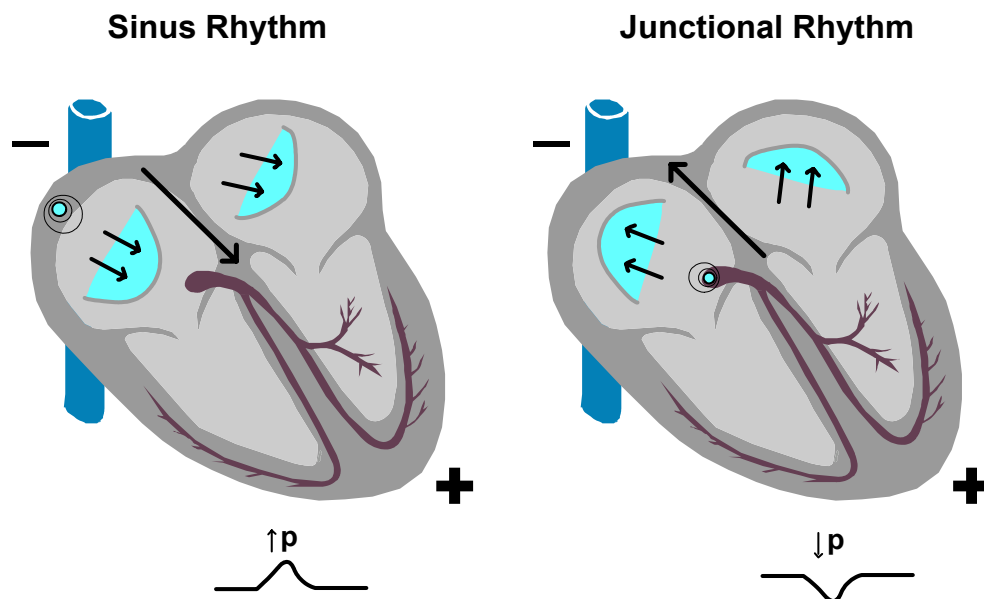


Figure 4.9 illustrates how the direction and shape of the P wave helps to locate the site of an originating supraventricular impulse. Lead II has its positive electrode near the heart's apex.

Ventricular depolarization moving towards a positive electrode also produces an upright waveform. The resulting waveform, though, is often more complex than the P wave produced by atrial depolarization. Ventricular depolarization (QRS complex) normally traverses three or four areas of the ventricles simultaneously thanks to the bundle branches.

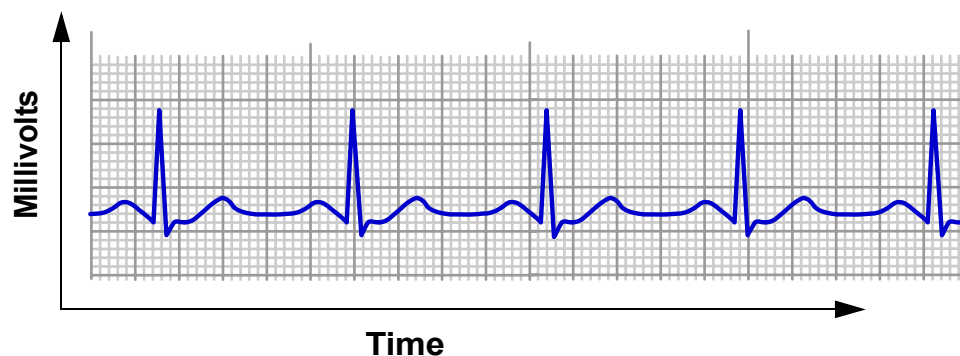
The QRS complex would likely be called just a Q wave if ventricular depolarization resulted from only one wave like what occurs in the atria. Kidding aside, the *direction* of the QRS complex is usually only considered with 12 lead ECG interpretation particularly when determining the electrical axis of ventricular depolarization (more on this in chapter seven). For single and dual lead views, only the *width* of the QRS complex is useful for rapid ECG interpretation.

The direction of the P wave, though, is an important consideration for rapid ECG interpretation. Based on a principle of vector theory, the P wave can provide insight into the location of an impulse that originates above the ventricles. Equipped as well with the knowledge that a narrow QRS complex is produced by a supraventricular impulse, the identification of supraventricular rhythms is definitely within reach.

Basic ECG Components

Having reviewed the cardiac monitoring system, ECG paper and vector theory, we are set to make sense of the basic ECG components. The ability to interpret an ECG relies heavily on a good understanding of these components.

Figure 4.11 The Scales of the ECG



An ECG is composed of a series of waves and lines usually ordered into some repeatable pattern. The waves and lines are displayed on either a two dimensional screen or on ECG paper. As mentioned earlier, the height of the tracing represents millivolts while the width of the ECG addresses an interval of time (see Figure 4.11).

Table 4.3 Normal and Abnormal Parameters of ECG Components

ECG Components	Normal Parameters	Abnormal Parameters	Causes of Abnormal Parameters
P Wave	Upright in most leads including lead II. Duration: < 0.11 seconds Amplitude: 0.5-2.5 sec.	Inverted Notched or tall	Junctional Rhythm Atrial rhythm, atrial hypertrophy
PR Interval	Duration: 0.12 - 0.20 sec.	Duration: shorter or longer than normal	Junctional rhythm, Wolff-Parkinson-White syndrome
Q Wave	Duration: <0.04 seconds Amplitude: <25% the amplitude of the R wave	Duration: 0.04 sec. or longer Amplitude: at least 25% the amplitude of the R wave	Myocardial infarction
QRS Complex	Upright, inverted or biphasic waveform Duration: < 0.11 seconds Amplitude: 1 mm or more	Duration: 0.11 second or more	Bundle branch block, ventricular ectopic i.e. PVC
QT Interval	Duration: less than 1/2 the width of the R-R interval	Duration: at least 1/2 the R-R interval	Long QT syndrome, cardiac drugs, hypothermia, subarachnoid hemorrhage Short QT associated with hypercalcemia
ST Segment	In line with PR or TP segment (baseline) Duration: shortens with increased heart rate	Deviation of 0.5 mm or more from baseline	Cardiac ischemia or infarction, early repolarization, ventricular hypertrophy, digoxin dip, pericarditis, subarachnoid hemorrhage
T Wave	Upright, asymmetrical and bluntly rounded in most leads Duration: 0.10-0.25 sec. Amplitude: less than 5 mm	Peaked, inverted, biphasic, notched, flat or wide waveforms	Cardiac ischemia or infarction, subarachnoid hemorrhage, left-sided tension pneumothorax, left bundle branch block, hyperkalemia, hypokalemia
U Wave	Upright Amplitude: < 2 mm	Peaked or Inverted Amplitude: > 2 mm	Hypokalemia, cardiomyopathy, ventricular hypertrophy, diabetes, digoxin, quinidine

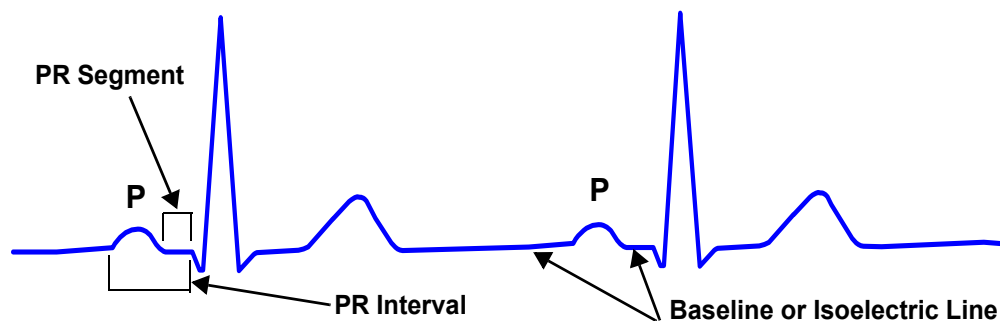
Table 4.3 outlines the parameters that define normal and abnormal ECG components. An incomplete list of possible causes of the abnormal waves, intervals and segments is included.

This section on ECG components addresses each of the waves, intervals and segments of an ECG in the order that they would appear. While waves are fairly self-explanatory, **intervals** measure time from the start of one wave to the start of another wave (an interval includes at least one wave) and **segments** measure time between waves (waves are not included in a segment). Table 4.3 outlines the parameters that are expected of normal and abnormal ECG waves, segments and intervals.

The P Wave, PR Segment and PR Interval

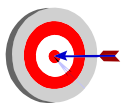
The **P wave** represents the depolarization of the right and left atria. The P wave begins with the first deviation from **baseline** and finishes when the wave meets the baseline once again. While the P wave is an electrical representation and not mechanical, a P wave strongly suggests that the atria have followed through with a contraction.

Figure 4.12 The P Wave, PR Segment and PR Interval



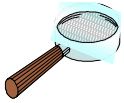In Figure 4.12, several ECG components are labelled. Note that a waveform is produced when the electrical potential of cardiac cell membranes change. During atrial depolarization, the atrial cell membranes quickly become more positive producing a P wave. The baseline or isoelectric line represents nothing more than an absence of voltage change to the cardiac cells.

The **PR segment** is the line between the end of the P wave and the beginning of the QRS complex. The PR segment signifies the time taken to conduct through the slow AV junction. This delay allows for atrial kick. The PR segment also serves as a benchmark for the isoelectric line.



The **baseline** or **isoelectric line** is a reference point for the waves, intervals and segments. While the PR segment is often used as the baseline, the TP segment - between the end of the T wave and the beginning of the P wave - is now generally seen as a more accurate baseline. Note: with fast rates, the TP segment disappears, leaving you with the PR segment as the next best, and only, baseline.

The **PR interval** is measured from the start of the P wave to the start of the QRS complex. While it might appear obvious that this is indeed a PQ interval, a Q wave is not always present on an ECG tracing. For consistency, the term is PR interval has been adopted whether a Q wave exists or not.



The **PR interval** can provide clues to both the location of the originating impulse and the integrity of the conduction pathways of the heart. A PR interval longer than normal (greater than 0.2 seconds) suggests that conduction is abnormally slow through the AV junction. This phenomenon is called **first degree AV block**. A PR interval shorter than normal (less than 0.12 seconds) occurs commonly with **junctional rhythms** (the impulse begins somewhere in the AV junction) because part of the conduction pathway - the atria and part of the AV junction - is bypassed and thus shortened.

The PR interval covers the time taken for the impulse to travel from the SA node through the atria and the AV junction through to the Purkinje network. Most of the PR interval is taken by the slow conducting AV junction. **Changes to the PR interval often points to the AV junction** (see box above). A normal PR interval is 0.12-0.20 seconds, which is the equivalent to 3-5 small squares (3-5 mm) on ECG paper.

If an ECG shows P wave, QRS complex - P wave, QRS complex - P wave, QRS complex - atrial depolarization, ventricular depolarization until the cows come home, a rather important relationship between the atria and the ventricle is revealed. **If the P wave is consistently followed by a QRS complex across a consistent PR interval, this is strong evidence that the originating impulse is supraventricular.** A consistent PR interval is often sufficient to declare that this is a supraventricular rhythm.

The QRS Complex

ECG interpretation relies heavily on the QRS complex. The QRS complex represents the depolarization of the ventricles. The repolarization of the atria is also buried in the QRS complex.

The normal depolarization of the ventricles is illustrated in Figure 4.13 on the next page. Three distinct waveforms are often present in a normal QRS complex. These waveforms follow the pathways of ventricular depolarization. Depolarization of the ventricular septum proceeds first from left to right away from the positive electrode in lead II. This early depolarization causes a small downward deflection called a **Q wave**.

A Q wave is the first negative deflection of the QRS complex that is not preceded by a R wave. A normal Q wave is narrow and small in amplitude (see Table 4.3 on page 80). Note that a wide and/or deep Q wave may signify a previous myocardial infarction (MI). More on the signs of cardiac ischemia and infarction is addressed in the next section.

Figure 4.13 The QRS Complex, ST Segment and the T Wave

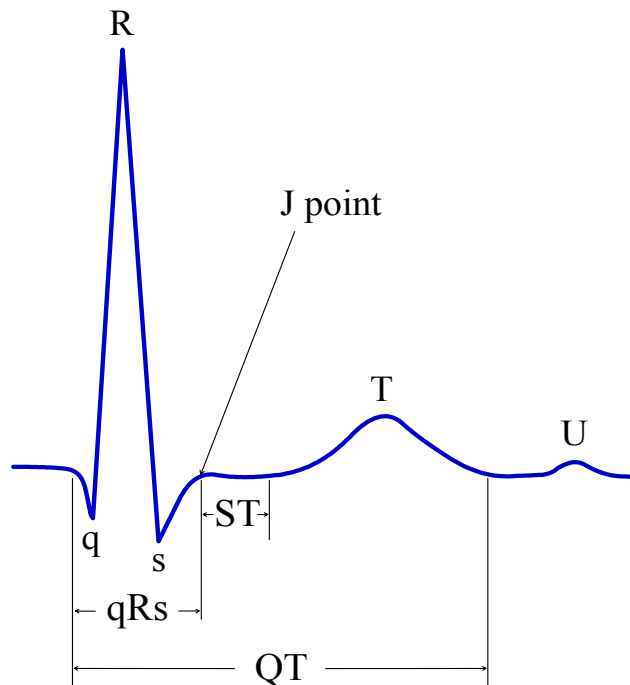
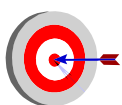


Figure 4.13 depicts the component parts of the QRS complex. The QRS complex consists of a series of waves, the 'Q', 'R', and 'S' waves. The 'Q' wave is the first negative deflection from baseline. The 'R' wave is the first positive deflection above baseline. The 'S' wave follows the 'R' wave with a negative deflection. A QRS complex may or may not have all three waveforms. The ST segment begins at the J point and continues to the beginning of the T wave.

Following the depolarization of the interventricular septum, ventricular depolarization then progresses from the endocardium through to the epicardium across both ventricles producing an R wave and an S wave. An **R wave** is the first positive deflection of the QRS complex. An **S wave** is the first wave after the R wave that dips below the baseline (isoelectric line). The end of the S wave occurs where the S wave begins to flatten out. This is called the **J point**.



Why is the QRS complex so much larger than the P wave? The ventricles are about 3 times the size of the atria. The larger ventricle will produce a larger waveform.

The waveforms of the QRS complex are often labelled with lower and upper case letters. Large waves are labelled with upper case letters. Smaller waves that are less than half the amplitude of the large waveforms are labelled with lower case letters. The QRS complex #2 in Figure 4.14 would be correctly labelled an rS complex. Nevertheless, it is quite common to keep things simple, calling it a QRS complex regardless of the size and labels of its various waveforms.

Abnormal ventricular depolarization produces a QRS complex that often has additional waveforms. For example, a second positive deflection of a QRS complex *after an R wave* is labelled **R'** (R prime). Similarly, a second S wave that dips below the baseline after the R wave is labelled **S'** (S prime). Refer to Figure 4.14 for an illustrated example. A downward **notch** in the R wave that does not dip below the baseline is simply called - yes - a notch in the R wave.

A narrow QRS complex occurs quickly over a period of less than 0.11 seconds (less than 3 mm in width). A narrow QRS occurs with normal ventricular depolarization that originates above the ventricles. Figure 4.14 provides a variety of different QRS complexes, produced by normal and abnormal ventricular depolarization. A normal, narrow QRS complex may be predominantly upright, predominantly inverted, completely inverted (called a QS complex) or biphasic (part upright, part inverted).

Figure 4.14 Various QRS Complex Morphologies

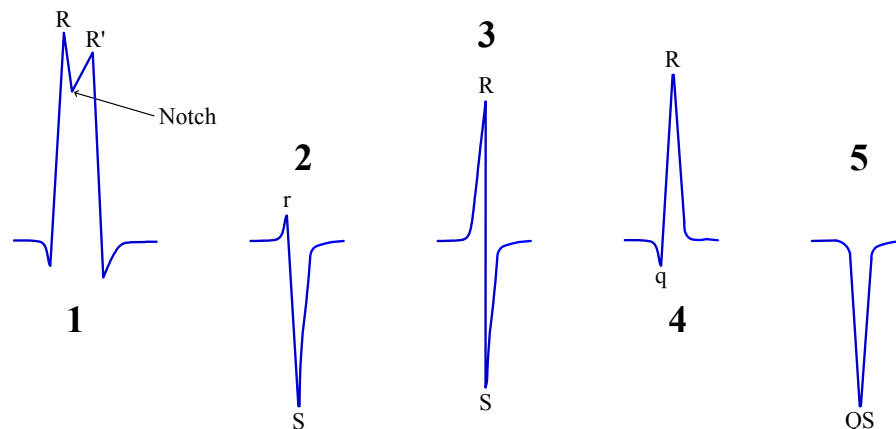


Figure 4.14 depicts several QRS complex shapes or morphologies. QRS complex #1 demonstrates the labelling convention for subsequent positive deflections above the baseline after the R wave. This second deflection is labelled R'. Note that a third upright deflection would be labelled R'' (R double prime). QRS complex #2-4 are all normal QRS complexes of different shapes. QRS complex #3 is a biphasic QRS complex would be labelled RS. The QRS complex #5 is a QS complex.

While the direction of the QRS complex is generally not important with basic ECG interpretation, the width of the QRS complex is key. As mentioned in Chapter 3, **the width of the QRS complex often indicates the location of the originating electrical impulse**. This is a rather important point since the first and foremost word of an ECG interpretation is the location of impulse initiation.

For example, rhythms that come from the SA node are *sinus* rhythms, from the AV junction are *junctional* rhythms, and that originate from the ventricle are *ventricular* rhythms. Simple. If the QRS is narrow - taking very little time to occur - the cardiac rhythm originates from a supraventricular site. Quickly determining whether the QRS is narrow or wide is a vital step in rapid ECG interpretation.

The Q Wave and The QT Interval

As mentioned in the previous section, a normal Q wave represents a depolarization of the ventricular septum, which usually travels from left to right, towards the right ventricle. When present, a Q wave is the first downward deflection of the QRS complex. While ST segment deviation is a sign of present events, a prominent Q wave points to an MI that has already occurred, recently to some time ago. A prominent Q wave is like a tattoo - once you have one, it's pretty much yours for good.

Figure 4.15 The Normal Q Wave and QT Interval

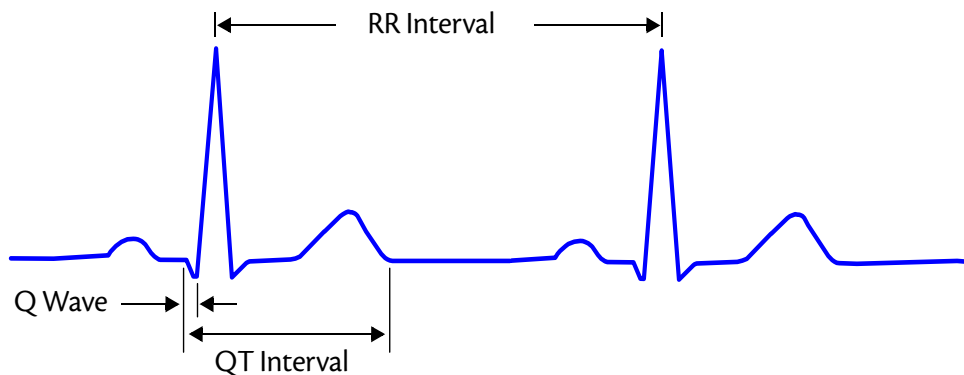
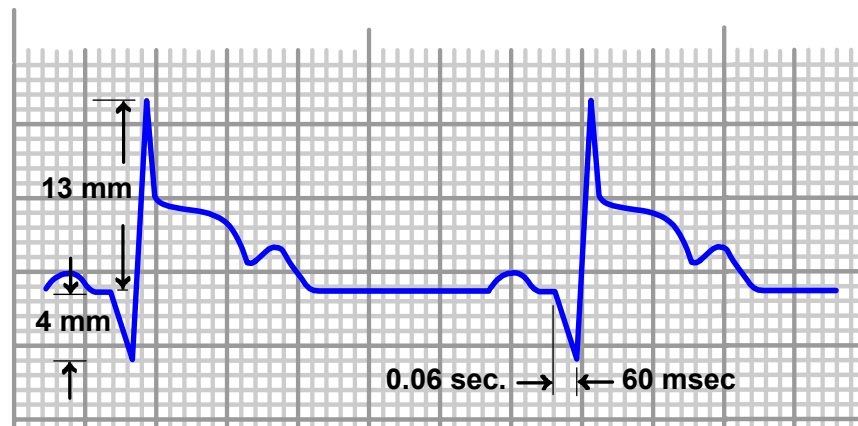


Figure 4.15 illustrates the Q wave, QT interval and the R-R interval. A normal QT interval should be less than half the R-R interval. A prolonged QT interval is associated with increased risk of R-on-T triggered lethal dysrhythmias.

A normal **Q wave** is usually no deeper than 2 mm and less than 1 small square in width (<0.04 seconds). An abnormal Q wave tends to get the most attention. A Q wave that is wider than 1 small square or at least 1/4 the height of the R wave is a significant marker of a myocardial infarction. In Figure 4.16, the Q wave is about 31% the height of the R wave ($4/13 = 31\%$), making the Q wave prominent. The width of the Q wave is also significant with a width of 0.06 seconds. This Q wave is typical of an MI.

Figure 4.16 Prominent Q Waves



The Q waves of Figure 4.16 are abnormal in both depth and width, findings that point to a previous myocardial infarction.

The QT interval represents a complete ventricular cycle of depolarization and repolarization. The QT interval is measured from the beginning of the QRS complex to the end of the T wave. A QT interval should be less than 1/2 the R-R interval.



A **long QT interval** wider than 1/2 the R-R interval is a significant risk factor for developing hemodynamically unstable dysrhythmias such as ventricular tachycardia and torsades de pointes. A prolonged QT interval is also associated with a higher incidence of sudden death.

The concern around a longer QT interval centers around the possibility of the next QRS coming at the tail end of the T wave, called an R-on-T phenomenon. This phenomenon can potentially cause dangerous dysrhythmias such as torsades de pointes. Causes of prolonged QT intervals include long QT syndrome, antiarrhythmics such as quinidine and procainamide, tricyclic antidepressants, and hypokalemia.

The ST Segment

Between the QRS complex and the T wave, lies the ST segment. The ST segment usually follows the isoelectric line. The ST segment represents early repolarization of the ventricles. Explained in detail in Chapter 6, early repolarization includes a plateau phase where the cardiac cell membrane potential does not change.

During early repolarization, the positive ion potassium exits the cardiac cell while the positive ion calcium enters the cardiac cell, effectively negating any change in cell membrane potential. Because the cell membrane does not change its electrical potential, ECG leads do not record any electrical activity. As a result, the ST segment usually lies along the ECG baseline.

Determining where the ST segment begins is determined by the J point. The J point, the juncture of the QRS and the ST segment, defines the starting point of the ST segment. The J point marks where the QRS complex changes direction, forming a notch or bump in the ECG tracing. The ST segment is evaluated for any deviation from the ECG baseline 0.04 seconds (1 mm) after the J point.

While ST deviations may be a normal occurrence for a subset of the population, most often ST deviation is a sign of either myocardial ischemia, myocardial infarction and/or cardiac disease. **It makes sense, then, to report any finding of ST deviation from baseline in the ECG interpretation** i.e. sinus rhythm with ST depression.

Figure 4.17 ST Segment Deviations

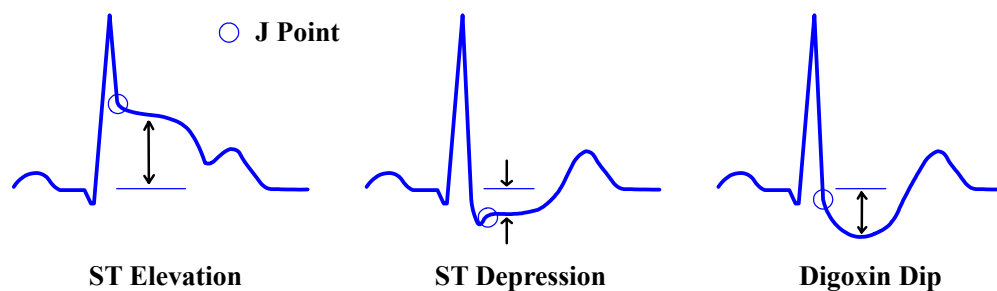
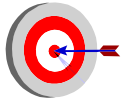


Figure 4.17 presents three examples of ST deviation. A digoxin dip is also called a “dig dip”.

ST depression of 1 mm or more in **2 contiguous leads** (neighboring leads) is suggestive of myocardial ischemia, injury or infarction. **ST elevation** of 1 mm or more in 2 contiguous leads is highly suggestive of a myocardial injury or infarction. Note that ST changes (elevation or depression) are highly suggestive of current events - **the acute coronary events are happening now.**

The shape of the ST segment, if depressed, bears mention. The depressed ST segment often presents horizontal (see the center QRS complex of Figure 4.17), sloping downwards or sloping upwards. Although all morphologies can indicate myocardial ischemia, the horizontal and downward sloping depressed ST segments are the more likely morphologies that point to ischemic events.

Note that ST changes can occur from conditions other than myocardial ischemia. As mentioned, ST elevation and depression may be a benign finding, although uncommon. For example, ST depression that is concave in shape - called a **dig dip** - can occur for patients taking digitalis (see Figure 4.17) even at normal blood levels. A depressed and upward sloping ST segment can represent **ventricular hypertrophy**.



ST segment elevation is a common finding in young healthy adults of African descent. This phenomenon is attributable to normal **early repolarization** and not a result of cardiac disease. Using an ECG to diagnose a disease state in the absence of direct contact with the patient, a patient's clinical history and presentation is fraught with peril.

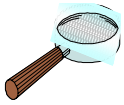The presence of ST elevation in most views of a 12 lead ECG suggests **pericarditis**. Ventricular rhythms and supraventricular rhythms with **left bundle branch block** have wide and bizarre QRS complexes, making the detection of ST changes all but impossible.

Several conditions not linked to cardiac ischemia can produce ST changes. The bottom line: most ST changes indicate cardiac ischemia, requiring urgent treatment BUT every ECG interpretation is more robust when integrated with a patient's clinical status and history.

The T Wave

Expect a T wave to follow every QRS complex. The T wave is a graphic representation of the repolarization of the ventricle. The T wave is typically about 0.10 to 0.25 seconds wide with an amplitude less than 5 mm. While ventricular depolarization occurs rapidly producing a tall QRS complex, ventricular repolarization is spread over a longer interval, resulting in a shorter and broader T wave.

The T wave is normally slightly asymmetrical and is usually larger than the P wave (see Figure 4.13 on page 83). The T wave is normally upright in lead II. Note that as heart rates increase, the P wave (atria) and the T wave (ventricles) begin to share the same space on an ECG. The larger T wave often covers the P wave. Note that the T wave is rarely notched. A notched T wave may also contain a P wave trying to show itself.



If ventricular repolarization returns cell membrane voltage back to its pre-depolarization resting electrical voltage, then **shouldn't the wave produced by ventricular repolarization be opposite that of ventricular depolarization?** In other words, should the QRS complex and the T wave face opposite directions, upright and inverted. This is usually not the case.

Ventricular depolarization proceeds from the endocardium to the epicardium, essentially depolarizing the ventricles from the inside out. It follows that repolarization also occurs from the inside out, producing inverted T waves opposite in direction to the QRS complex. Instead, repolarization is delayed in endocardial cells, allowing the epicardium to repolarize first. **Repolarization normally proceeds opposite to depolarization, from the outside in. An upright T wave results.**

An inverted T wave can point to cardiac ischemia among other causes. Ischemia to the epicardium prolongs ventricular repolarization to this area. This extended repolarization of the epicardium removes the delay between the repolarization of the endocardium and the repolarization of the epicardium, with *repolarization* now following the sequence of *depolarization*. An inverted T wave results.

Abnormally shaped T waves can signify acute episodes of cardiac ischemia, electrolyte imbalances, and the influence of cardiac medications. For example, peaked T waves can occur early during periods of myocardial ischemia and infarction. Later, cardiac ischemia may cause the T wave to invert. Electrolyte imbalances can also affect the T wave. Hyperkalemia is often associated with peaked T waves. Hypokalemia can flatten the T wave. Quinidine can widen the T wave while digitalis can flatten the T wave.

Abnormally shaped T waves can also occur following injury to the lungs or the brain. While the physiology is not well understood, T wave inversion can occur with a left-sided tension pneumothorax. Peaked or inverted T waves have also been reported with brain injury, specifically subarachnoid hemorrhage.

Figure 4.18 Normal and Abnormal T Waves

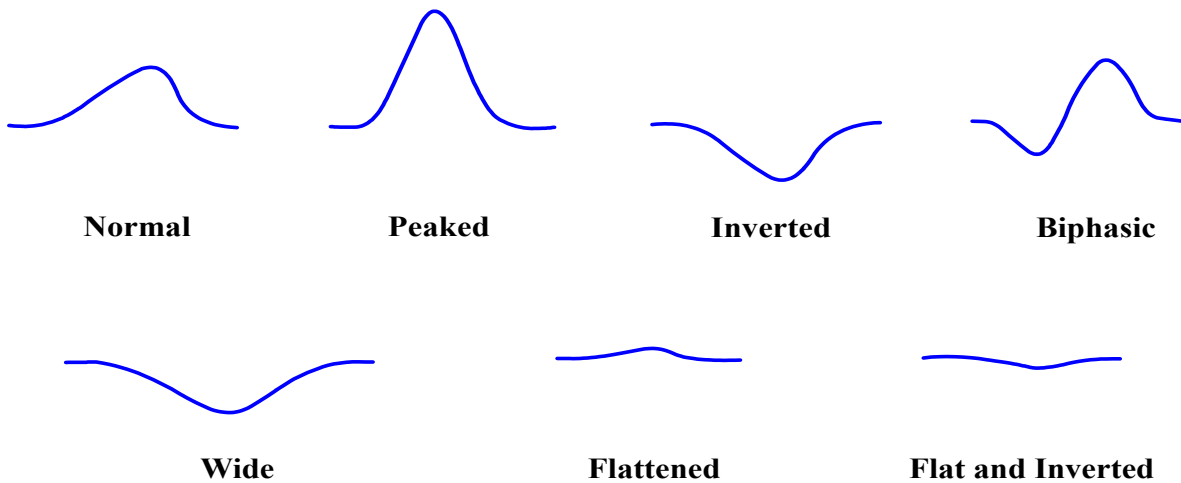


Figure 4.18 illustrates a variety of T waves, both normal and abnormal. A normal T wave is upright and slightly asymmetrical. During ischemic episodes, T waves may initially peak, then invert. Electrolyte imbalances such as hyperkalemia can cause the T wave to peak while hypokalemia is associated with flattened T waves. Certain medications such as quinidine can slow repolarization and widen the T wave while digoxin can flatten the T wave.

Abnormally shaped T waves are also commonly benign, muddying the clinical picture for practitioners. All morphologies of T waves, from normal to peaked to inverted are not uncommonly present in healthy individuals without any evidence of disease, cardiac or otherwise. This makes the T wave a weak sign for any diagnosis. The T wave must be placed along side other clinical evidence. Rarely would treatment be based solely on the shape of the T wave.

The U Wave

Occasionally, another wave -the **U wave**- is recorded immediately following the T wave and before the P wave. The U wave remains rather mysterious but is thought to represent a final stage of repolarization of unique ventricular cells in the midmyocardium. The U wave will most often orient in the same direction as the T wave with an amplitude less than 2 mm.

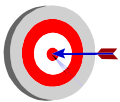
An abnormal U wave is inverted or tall with an amplitude of 2 mm or more. An abnormally tall U wave is associated with conditions such as hypokalemia, diabetes, ventricular hypertrophy, and cardiomyopathy. Cardiac medications such as digoxin and quinidine can also cause a tall U wave.

The U wave the series of waves, intervals and segments that form the ECG. Knowing what to expect from each of these components prepares you to quickly recognize deviations from the norm. Before looking to the QRS complex and the R-R interval to determine heart rate, let's take a moment to differentiate between heart rate and pulse rate.

Heart Rate and Pulse Rate

Heart rate is the number of QRS complexes - the number of ventricular depolarizations - present in a minute. **Heart rate is not always the same as pulse.** Heart rate is a measurement of electrical activity while pulse ensures the perfusion of the blood to the target tissues.

Many have been caught depending on the cardiac monitor for vital information such as heart rate. For example, patients with electronic pacemakers may display heart rates twice the pulse rate. This occurs because the QRS complex produced after the pacer spike also may count as a separate QRS complex, thus doubling the heart rate.



A special case of the disparity between heart rate and pulse can occur with ventricular bigeminy. **Ventricular bigeminy** is a cardiac rhythm with PVCs every alternate QRS complex. If the PVCs do not have a corresponding pulse, the pulse rate would be equal to 1/2 the heart rate displayed on most cardiac monitors. A seemingly adequate heart rate of 70/minute may have a pulse of only 35/minute!

Another example of a serious disparity between heart rate and pulse occurs with premature ventricular complexes (called PVCs). The PVCs come early and cause short filling times. It follows then that the ventricles stretch minimally and subsequently contract ineffectively. The outcome: many PVCs fail to produce a perfusing pulse and the peripheral pulse is less than the heart rate displayed by the cardiac monitor (which includes both normal QRS complexes and PVC complexes).



The patient - not the monitor - is the gold standard.

This cannot be said enough. Most of us have been caught at one time or another relying on the cardiac monitor to the exclusion and great risk of the patient.

Heart rate is virtually always provided on the screen of a cardiac monitor. This number may offer some value but taking a patient's pulse is always good practice. Don't get burned.

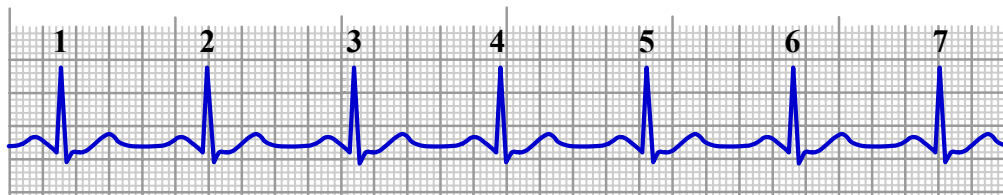
Calculating Heart Rate

Heart rate is a function of time. To measure heart rate from an ECG, a rhythm strip of ECG is required. As mentioned earlier, ECG paper provides a scale to measure time (25 mm = 1 second) including hash marks at either the top or bottom of the graph paper to indicate 1 second and/or 3 second intervals. Three methods for calculating heart rate are commonly used: the six second count, the triplicate method and the caliper method.

The Six Second Count

Perhaps the simplest and most common method to determine heart rates involves multiplying the number of QRS complexes found over six seconds by a factor of 10 to get the number of QRS complexes in a minute (60 seconds). Figure 4.19 provides an ECG over a six second period. What is the heart rate per minute for this rhythm strip?

Figure 4.19 The 6 Second Count Method to Determine Heart Rate.



$$7 \text{ QRS complexes in 6 seconds} \times 10 = 70 \text{ QRS complexes/minute}$$

Simple stuff. This method - call it **the six second count** - works well whether the rhythm is regular or irregular. Mind you, if the rhythm is grossly irregular, a longer rhythm strip may produce a more accurate heart rate i.e. 15 seconds of QRS complexes multiplied by 4. Note that the six second count also works well for slow rhythms.

The Triplicate Method

The **triplicate method** is useful for measuring heart rate over shorter periods (less than 3 seconds) or for calculating heart rates of rapid tachycardias. This method is quick but not quite as accurate at measuring heart rate as the six second count method. **Note: the rhythm must be regular (consistent R-R interval) for the triplicate method to be of any use.**

Understanding the triplicate method calls on the fact that a large square on ECG paper equals 5 mm or 0.20 seconds ($5 \text{ mm} \times 0.04 = 0.20 \text{ seconds}$ or $1/5$ of a second). Begin by finding an R wave that falls on a thicker vertical line in Figure 4.19 of the previous page (the second QRS complex). If the next R wave and every subsequent R wave occurred only one large square apart, how fast is the resulting heart rate?

$$1 \text{ QRS every } 1/5 \text{ of a second} = 5 \text{ QRS/second} = 300 \text{ QRS/minute}$$

Fast. If the R waves consistently arrived two large squares apart, the heart rate would be half of 300 at 150/minute. If the R waves are three large squares apart, the heart rate would be a third of 300/minute at 100/minute. Four large squares in between R waves equals a heart rate of 75/minute. A rate of 60/minute occurs with R-R intervals of five large squares.

Figure 4.20 Triplicate Method to Determine Heart Rate

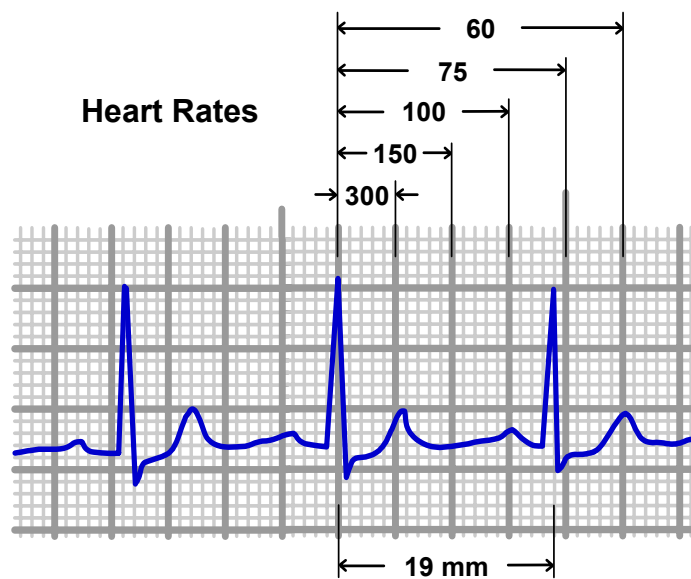


Figure 4.20 illustrates the triplicate method to estimate heart rate with only two QRS complexes. The triplicate method is particularly useful when measuring the heart rate of an underlying rhythm when frequent ectopic beats are also present. This method can be used only for rhythms with a consistent R-R interval. For rhythms with irregular patterns, the six second count is preferable for measuring heart rate.

In figure 4.20, the second QRS complex falls on a thick vertical line. The next R wave is between three large squares (thick lines) and four large squares away. The heart rate is estimated between 75/minute and 100/minute. Because the next R wave falls closer to the fourth thick line, the rate is closer to 75/minute. The heart rate is about 80/minute, a safe approximation from a treatment perspective. Would a heart rate of 77/minute or 85/minute be any more meaningful? Not likely.

The Caliper Method

If you did want an exact rate, you could count the number of millimeters across the R-R interval. This is often accomplished with the use of calipers. ECG paper records at a rate of 25mm/second which would total 1500 mm if allowed to print for a full minute (60 seconds x 25mm/second = 1500mm). Divide the total of 1500 by the R-R interval (in millimeters) to arrive at the number of QRS complexes per minute.

Revisiting Figure 4.20, the R-R interval is measured to be 19 mm.

$$1500 / 19 = 79 \text{ QRS complexes per minute}$$

$$\text{Heart Rate} = 79/\text{minute}$$

An earlier approximation using the triplicate method of 80/minute wasn't far off the mark. Note that for regular rhythms (R-R interval is consistently the same), all three methods are effective in determining rate. **For irregular rhythms with fluctuating R-R intervals, the six second count is the only useful method for measuring heart rates.**

Summary

This chapter served as an ECG primer, outlining the cardiac monitoring system, ECG components and three methods to determine heart rate. The electrocardiogram is a graphical representation of cardiac electrical activity measured over time. The amplitude or height of waveforms reflects differences in voltage across the heart while the width of the ECG reflects intervals of time. Specialized paper records an ECG at a speed of 25 mm/second.

An ECG is recorded and displayed with a cardiac monitoring system. Ongoing monitoring is provided via 3 lead, 5 lead and modified 12 lead systems. The basic 3 lead ECG remains a common monitoring configuration, placing electrodes near the right shoulder (white), the left shoulder (black) and the lower left lateral area just below the ribs (red). There is a variety of 5 electrode systems that provide five lead views to as many as 12 lead views with the EASI™ or interpolated 12 lead systems.

The heart is viewed from the perspective of the electrode with the positive polarity, viewing the heart toward its negative counterpart. For example, lead II with the positive red electrode, looks up at the apex of the heart towards the white electrode (negative).

The positive electrode is also important in determining the direction of waveforms. Electrical activity that depolarizes towards the positive electrode produces an upward deflection.

The waveform produced by atrial depolarization is the P wave. The appearance of a P wave before a QRS complex strongly suggests atrial kick. Ventricular depolarization results in a QRS complex. A narrow QRS (rapid depolarization) occurs when rhythms are supraventricular in origin. The PR interval is the time between the beginning of atrial and ventricular depolarization. The T wave is the repolarization of the ventricles.

The ST segment and Q wave are also significant. Deflections of the ST segment more than 1 mm above or below the baseline in 2 contiguous leads is a diagnostic sign of cardiac ischemia and/or myocardial injury. While ST elevation is most commonly a sign of myocardial infarction (MI), ST depression can signify cardiac ischemia or myocardial infarction. The presence of a Q wave that is 1 mm wide and/or at least 25% the height of the QRS complex points to a completed MI.

The QT interval, the full ventricular cycle of depolarization and repolarization, should be less than half the R-R interval. Longer QT intervals are associated with R-on-T phenomenon yielding ominous rhythms such as ventricular tachycardia, torsades de pointes and ventricular fibrillation.

Heart rates and pulse rates can be quite distinct. The gold standard remains the pulse rate measured on the patient. Methods to determine heart rate include the six second count, the triplicate method and the caliper method. The preferred method often depends on the regularity and speed of the cardiac rhythm.

Chapter Quiz

1. Lead II, an inferior lead, views the apex of the heart.

True or False

2. Atria depolarization towards a positive electrode in lead II results in an upward P wave.

True or False

3. The rate by which the ECG normally prints on paper is 50 mm/second.

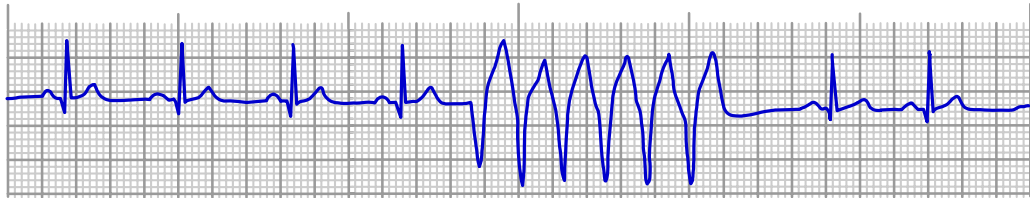
True or False

Answers: 1. True; 2. True; 3. False

4. The QRS complex represents both ventricular depolarization and atrial repolarization.

True or False

Questions #5-8 refers to the six second ECG below.



5. The sinus rhythm for this ECG has a heart rate of _____/minute.

6. Would a patient with this ECG have an atrial kick during the burst of rapid ventricular beats?

Yes or No

7. The QT interval for the underlying sinus rhythm is normal.

True or False

8. The width of the QRS complex for the sinus rhythm is _____ seconds.

9. The coloring schemes for ECG lead wires are standardized by (circle all that apply):

- a) American Heart Association (AHA)
- b) American Medical Association (AMA)
- c) International Electrotechnical Commission (IEC)
- d) Manufacturers of cardiac monitors

10. Lead I views which area of the heart?

- a) apex of the heart
- b) lateral left ventricle
- c) right ventricle
- d) posterior right ventricle

11. The presence of ST depression in lead II and lead III points to cardiac ischemia or infarction to the (left lateral, inferior, septal) region of the heart.

Answers: 4. True; 5. approximately 90/minute; 6. No; 7. True; 8. 0.06 seconds; 9. a),c); 10. b); 11. inferior

12. An ECG lead views the heart from the perspective of the positive electrode viewed towards the negative electrode.

True or False

13. Which of the following statements is **false** regarding dysrhythmia monitoring?

- a) the more ECG lead views, the better
- b) a 12 lead ECG can differentiate between ventricular tachycardia (VT) and supraventricular tachycardia (SVT) 90% of the time
- c) the use of lead MCL₁ is associated with 22% more errors in differentiating VT and SVT than using lead V₁
- d) lead II is the best lead view for dysrhythmia monitoring

14. A single lead view is often sufficient for dysrhythmia monitoring but seldom sufficient for cardiac ischemia monitoring.

True or False

15. According to the American Heart Association, the color configuration of the 5 lead ECG system is:

Left Arm (LA)	_____
Right Arm (RA)	_____
Left Leg (LL)	_____
Right Leg (RL)	_____
Lead V ₁ or V ₅	_____

16. Lead II from a three lead system always appears identical to lead II of a 12 lead ECG.

True or False

17. Lead fingerprinting refers to:

- a) based on a patient's history, choosing the ECG lead that monitors an area of the heart most likely to have ischemic episodes
- b) the appearance of Q waves in ECG leads that view regions of the heart that have infarcted
- c) the presence of two contiguous leads that display ST elevation, diagnostic of a myocardial infarction
- d) smudging the ECG strip with your fingers

Answers: 12. True; 13. d); 14. True; 15. LA-black, RA-white, LL-red, RL-green, V₁ or V₅-brown; 16. False; 17. a)

18. The interpolated 12 lead ECG includes four (limb, precordial) electrodes and two (limb, precordial) electrodes.

19. A normal small Q wave is the result of:

- a) atrial depolarization
- b) interventricular depolarization
- c) posterior ventricular depolarization
- d) depolarization of the midmyocardium

20. A wave of depolarization that travels towards a lead's positive electrode, produces an upright waveform on an ECG.

True or False

21. Of the ECG components, an interval can include (circle all that apply):

- a) wave(s)
- b) segment(s)
- c) voltage changes in the heart
- d) all of the above
- e) none of the above

22. Ventricular contraction and ventricular depolarization occur simultaneously.

True or False

23. The PR interval measures the period for the electrical impulse to travel:

- a) from the SA node to the bundle of His
- b) through the atria
- c) from the SA node to the Purkinje network
- d) across the AV junction

24. A consistent PR interval across a six second ECG strongly supports the claim that:

- a) the rhythm originates at the AV junction
- b) the rhythm originates above the ventricles
- c) the rhythm originates from the SA node
- d) ventricular depolarization progresses along a normal pathway

25. Ventricular systole begins with the (QRS complex, ST segment, T wave).

26. Characteristics of an ECG that suggest a myocardial infarction include (circle all that apply):

- a) ST segment elevation in two contiguous leads
- b) ST depression in two contiguous leads
- c) inverted T waves
- d) deep or wide Q waves
- e) tall P waves

27. A normal QRS complex can be (circle all that apply):

- a) upright
- b) inverted
- c) biphasic
- d) wide

28. A QT interval longer than 1/2 the R-R interval increases the risk for which events to occur (circle all that apply):

- a) R-on-T phenomenon
- b) torsades de pointes
- c) ventricular tachycardia
- d) ventricular fibrillation

29. ST deviation is always a sign of cardiac ischemia.

True or False

30. Peaked T waves can signify (circle all that apply):

- a) normal repolarization of the ventricles
- b) cardiac ischemia
- c) hyperkalemia
- d) subarachnoid hemorrhage
- e) left-sided tension pneumothorax
- f) myocardial infarction
- g) atrial hypertrophy

Answers: 26. all but e); 27. all but d); 28. all; 29. False; 30. all but g)

Suggested Readings and Resources



Adams-Hamoda, M. et al. (2003). Factors to Consider When Analyzing 12-Lead Electrocardiograms for Evidence of Acute Myocardial Ischemia. *American Journal of Critical Care* (12) 1. Also found at:
[http://www.aacn.org/pdfLibra.NSF/Files/Adamsfinal/\\$file/Adams.pdf](http://www.aacn.org/pdfLibra.NSF/Files/Adamsfinal/$file/Adams.pdf)

Cowley, M. (2002). *A Practical Guide to ECG Monitoring and Recording*. Found at <http://www.mikecowley.co.uk/leads.htm>.

Drew, Barbara J.(2002). Celebrating the 100th Birthday of the Electrocardiogram: Lessons Learned from Research in Cardiac Monitoring. *American Journal of Critical Care* (11) 4. Also found at
[http://www.aacn.org/pdfLibra.NSF/Files/Drewjul02/\\$file/Drewfinal.pdf](http://www.aacn.org/pdfLibra.NSF/Files/Drewjul02/$file/Drewfinal.pdf)

Macfarlane, P.W. and Coleman, E. N. Resting 12-Lead ECG Electrode Placement and Associated Problems. Found at <http://www.scst.org.uk/coleman/resting.htm>.

Philips Medical Systems. (2002). EASI 12-Lead Algorithm. Found at:
http://www.medical.philips.com/main/products/resuscitation/assets/docs/algorithm_s/easi_12lead_technical_overview.pdf

Smith, Stephen W. (2002). *The ECG in Acute MI*. New York: Lippincott Williams and Wilkins

What's Next?

The ECG primer completed the core basics necessary to make sense of ECGs. It is time to put it all together. Chapter 5 weaves together the concepts and major points presented thus far into a simple four step method to rapidly interpret ECGs. This brief chapter does not delve into new material but rather quickly makes use of the four step method with ample opportunity for practice. Now that the ECG is seen for what it truly represents, ECG interpretation can be simple, fast and meaningful.